SPONTANEOUS PNEUMOTHORAX: PRIMARY MANAGEMENT - CHW

PRACTICE GUIDELINE ©

DOCUMENT SUMMARY/KEY POINTS

Note: This protocol is for spontaneous pneumothorax management and should **not** be used for cases of traumatic pneumothorax.

- This protocol has been revised on the basis of an audit reviewing the management patterns of children presenting with primary spontaneous pneumothorax at the Children's Hospital at Westmead from 2009-2019 (Lieu N, Ngo P, Robinson PD), and recent literature highlighting non-inferior outcomes of conservative versus interventional management approaches.

CHANGE SUMMARY

- Due for mandatory review. No changes made.

READ/ACKNOWLEDGEMENT

- Clinical staff in CHW Emergency Department should be aware of this document.

This document reflects what is currently regarded as safe practice. However, as in any clinical situation, there may be factors which cannot be covered by a single set of guidelines. This document does not replace the need for the application of clinical judgement to each individual presentation.

Approved by:	SCHN Policy, Procedure and Guidelines Committee	
Date effective:	1st August 2024	**Review Period:** 3 years
Team Leader:	Resident Medical Officer	**Area/Dept:** Respiratory Medicine

TABLE OF CONTENTS

Background

Classification

1. **Spontaneous**
   - **i.** Primary (PSP)
   - **ii.** Secondary (pre-existing lung disease)
2. **Traumatic**
   - **i.** Penetrating or blunt trauma to chest
3. **Iatrogenic**
   - **i.** Complication of diagnostic or therapeutic intervention

Estimated incidence of Primary Spontaneous Pneumothorax (PSP)

The estimated incidence of PSP is 7.4 – 18 per 100,000/yr in males and 1.2 – 6 per 100,000/yr in women[1,2]. The true paediatric incidence is unclear[3]. Typically, patients are tall thin males aged 10-30, with PSP rare in people >40 yrs[4]. Most have no clinically apparent lung disease.

Clinical

Most occur at rest[5]. Virtually all have ipsilateral chest pain or acute shortness of breath (SOB). Pain may be minimal or severe. Initially it may be described as "sharp" and later as a "steady ache". Symptoms usually resolve in 24 hours, even if the pneumothorax doesn't.

Examination may be normal if the pneumothorax is small. Clinically it becomes more detectable as the size increases, with decreased air entry, hyper-resonant percussion note, and decreased chest wall movement.

Important: Exclude signs of **tension pneumothorax** – mediastinal shift (tracheal deviation, displaced apex), increasing respiratory distress, cyanosis, hypotension and tachycardia. If suspected then proceed immediately to needle thoracocentesis.

Chest X-ray (CXR) is diagnostic (however tension pneumothorax is a clinical diagnosis). An expiratory film may reveal a small apical pneumothorax not evident on the inspiratory film but routine use does not improve diagnostic yield[6]. In younger children, a lateral decubitus may be useful to demonstrate a localised collection. Clinical manifestations are not reliable indicators of size[5,7].

Prognosis

Recurrence occurs in an average of 30% of patients (16-52%) in 11 studies. Most occur within 6 months to 2 years after the initial episode[7]. Younger age and smoking are identified risk factors[8]. Ipsilateral subpleural bullae have been reported in 89% of CT scans in patients with PSP compared to 20% in controls (matched for age and smoking status). However CT presence of bullae is not predictive of recurrence[9]. Thus the presence of bullae alone, should not determine the treatment decisions regarding prevention.

Secondary pneumothorax

- Airway disease (e.g. Cystic fibrosis, Asthma)
- Infectious lung disease (e.g. PCP pneumonia, Necrotizing pneumonias (Anaerobic, gram negative bacteria, *Staph aureus*)
- Interstitial lung disease
- Connective Tissue disease (e.g. Marfan's, Ehlers-danlos)

There are a number of important differences to PSP[10]:

- The SOB is usually more severe and hypercapnia may be present
- Symptoms do not resolve spontaneously
- Examination findings may be more subtle as they can be masked by underlying disease
- Higher rates of recurrence occur, with >50% reported in patients with cystic fibrosis[11]

Management Protocol for Pneumothorax

Aims of Management

The aims of management are to:

- Eliminate the intrapleural collection of air
- Facilitate pleural healing
- Attempt to prevent recurrence

Pneumothorax should be considered in all children who develop unexplained shortness of breath, particularly when associated with unilateral chest pain.

Conservative vs Interventional management

Background and Recent Literature

There continues to be a lack of published paediatric literature to base guideline recommendations for the management of PSP in children.

In 2020, an important study examining the outcomes of conservative management in adolescents and adults was published. Brown et al. performed a multicentre, randomised, noninferiority trial across hospitals in Australia and New Zealand[12]. They assessed patients presenting with PSP between the age of 14-50 years (mean 26 years old) and found conservative management of PSP was non-inferior to interventional management. Results noted lower risk of adverse events (8% vs 27%), lower recurrence rates (94.4% vs 98.5%) and shorter length of hospital stay (1.6 vs 6.1 days). It is important to note that 25/162 (15.4%) patients in the conservative arm went on to receive intervention due to the following: clinically significant symptoms, haemodynamic instability or repeat CXR shows enlarging pneumothorax along with physiological instability.

Recent CHW experience

An audit was performed analysing the management patterns of children presenting to The Children's Hospital at Westmead (CHW) with PSP and SSP between 2009-2019, the period during which the last protocol was in place.

This protocol had focused on encouraging aspiration as a first line intervention prior to Intercostal Chest Catheter (ICC), and only conservative management in cases of small PSP with no significant symptoms.

The audit found the following:

- children with PSP who were managed conservatively had a lower recurrence rate (11%) when compared to those who underwent intervention (20%).
- when combined with the data of Australian and New Zealand ED centres (including CHW) published by Robinson et al in 2015[13], the data revealed an increasing trend favouring the use of a conservative approach over the last 20 years in children.
    - Between 2003-2010 42% of PSP and 30% of SSP were managed conservatively[13] compared to 49% of PSP and 34% of SSP from 2009-2019.

Therefore, the current treatment algorithm has now been revised to promote a greater degree of conservative management.

Aspiration vs. Insertion of Intercostal chest catheters

Background and Recent Literature

Adult British Thoracic Society (BTS) guidelines[14] recommended aspiration prior to insertion of ICC in large pneumothoraces (>2cm), while the American College of Chest Physicians (ACCP) guidelines[15] recommend aspiration in small pneumothoraces when there is concern of air leak after a period of observation. These guidelines were published prior to the study by Brown et al.

Recent CHW experience

The recent audit of CHW practice following introduction of the recommendation for aspiration as first line intervention, found that aspiration was rarely performed in practice: 84% of patients undergoing intervention continued to receive an ICC as first line intervention despite aspiration recommendations. Of the patients who underwent aspiration, 63% went on to require ICC or surgery.

A recent systematic review and meta-analysis comparing conservative management, aspiration and surgery in PSP also revealed aspiration has become unfavourable in several international studies[16,17].

This current treatment algorithm has therefore been revised to remove the recommendation for aspiration in the management of children with PSP or SSP.

Treatment Algorithm

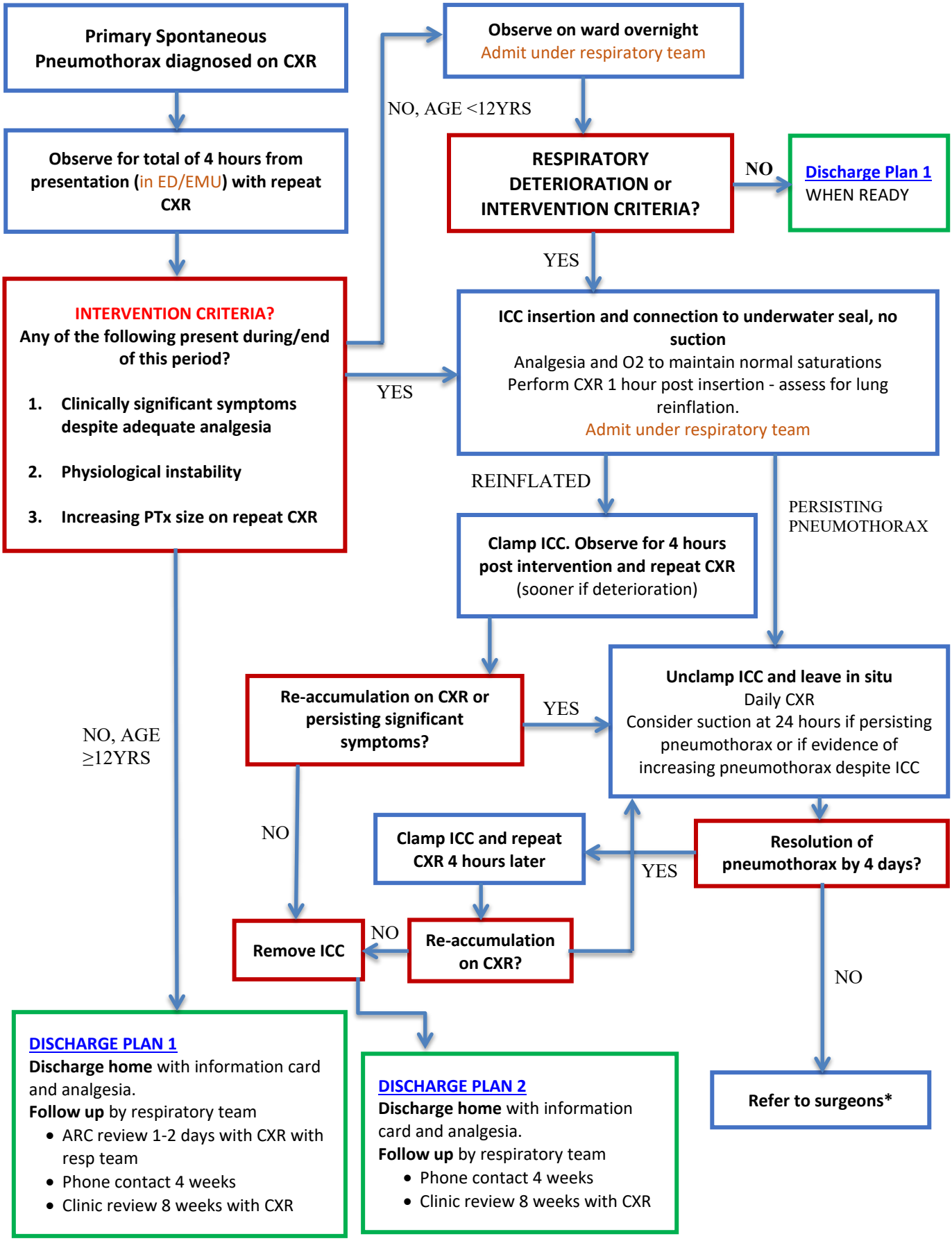

Size Definition

Background and Recent Literature

Historically, pneumothorax management recommendations have been based on pneumothorax size. Management recommendations in the 2021 updated protocol are based on whether a pneumothorax is *increasing* in size and not on classifying initial pneumothorax size on presentation as small or large. The description of how to appropriately size a pneumothorax remains in the protocol as this remains part of the management protocol for secondary pneumothoraces.

ACCP[15] and BTS[18] definitions of size classification differ and rely on uniformity of lung dehiscence which in reality is not always encountered. The suggested classification is based on features of both, to incorporate localised apical pneumothoraces:

- A pneumothorax is defined as "Large" when the volume of pneumothorax is >30% **or** ≥ 3cm apex to cupola distance

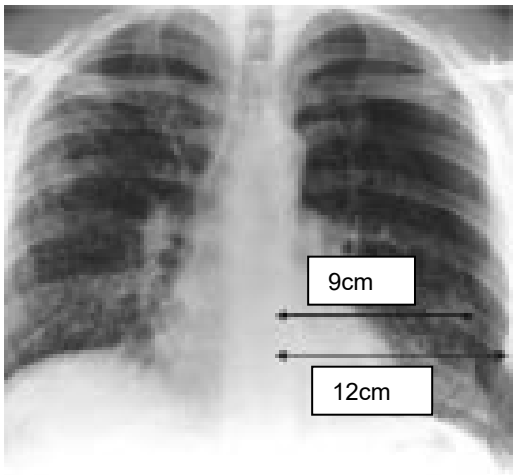

Volume of Pneumothorax (%) =

$$\frac{\text{Hemithorax diameter}^3 - \text{Lung diameter}^3}{\text{Hemithorax diameter}^3} \times 100$$

Measurements should be performed at the **hilum**.

For example:
$(12^3-9^3)/12^3 \times 100 = 50\%$

The flowchart on the next page outlines recommended management for PSP. All cases of PSP should be discussed with the Emergency physician on call to decide initial management. The Respiratory physician on call should be consulted if there are questions regarding initial management following discussion with the ED physician on call, if the child is being admitted, or to arrange follow up as outlined later in the protocol. Decisions regarding intervention may additionally require the input of the surgeon and interventional radiologist on call.

This document outlines management guidelines and each case should be evaluated on its own merits. **Specific points about secondary spontaneous pneumothorax management can be found in the further notes section**.

- Increasing size on CXR
  - Definition of adequate CXR = CXR taken in full inspiration. Outside film can be used as baseline if deemed adequate.
  - Both CXRs must be full inspiration films to allow accurate comparison of size.
- Standard analgesia defined as paracetamol or ibuprofen. Those requiring opiates would be admitted for observation regardless of other aspects of management until stable on standard analgesia.

- Physiological instability defined as any of the following:
  - Systolic hypotension
  - Tachycardia despite adequate analgesia
  - Saturations <90% in room air
  - Significant work of breathing

*see below for indications for surgical referral

See below for further details regarding follow up and discharge planning.

Further notes regarding acute management

Use of oxygen

Evidence supporting the use of O_2 to aid reabsorption of air is weak and therefore **O_2 is only indicated to maintain saturations ≥90%**, not to promote reabsorption of air from the pleural space. O_2 may also be considered for therapeutic comfort if a trial relieves symptoms of dyspnoea and shortness of breath.

Anaesthetic for Aspiration and ICC insertion

Nitrous oxide **IS CONTRAINICATED** during either procedure, as it enters the pleural space by diffusion, and can cause a rapid increase in the volume of the pneumothorax[19]. The choice of anaesthetic used is at the discretion of the physician performing/supervising the procedure. Supervision by the anaesthetist on call may be necessary in some patients. The use of intravenous ketamine is not recommended.

Please see separate protocol for performing these procedures. The insertion ICC should only be performed by medical staff experienced in the procedure, or under supervision by an experienced physician. Small bore ICC are as effective as large bore with fewer associated complications. Large bore ICC should only be considered in cases of persistent air leak where small bore ICC have failed (may indicate bronchopleural fistula). Small bore ICC are stocked in ED, PICU and Radiology.

Following insertion of an ICC, all ICC should be connected to underwater seal drainage (except in secondary pneumothorax when suction should be commenced – see below).

Consultation with the Interventional Radiologist on call should be considered in the event of:

- Younger children (age <12 years) with smaller body size making procedures more difficult
- Pneumothorax not accessible using standard approach
- Failure to aspirate air during attempted aspiration or failure of ICC insertion. Further imaging may aid correct drainage

Use of Suction

Suction should not be used initially with ICC, due to the documented risk of re-expansion pulmonary oedema, which has been reported in ≤14% treated initially with suction14. Risk factors include large pneumothoraces and age < 40 years. Mostly it is limited to being a radiological phenomenon, but has a reported mortality of 20% in patients who become clinically symptomatic. Suction should be used only if there is persisting air leak or failure lung re-expansion at 24 hours after ICC insertion, and should be a high volume, low pressure (10-20cm H_2O) circuit.

If secondary pneumothorax

There should be a lower threshold for intervention with ICC insertion given decreased baseline lung reserve and ability to compensate. The protocol for management differs from PSP in the following manner.

- All cases should be admitted for to the ward for observation under the Respiratory team.
- ICC should be considered for large pneumothoraces **and** unstable patients regardless of size.
- If ICC inserted, attach suction at 10-20cm H_2O to aid lung re-expansion

Transport of patients referred from other hospitals

Consultation with the Newborn and Paediatric Emergency Transport Service (NETS) is recommended for inter-hospital transfer of patients with documented pneumothorax. Transport of patients with a pneumothorax should ideally occur by road. However, due to potential distances involved this may not always be practical. If patients are being transferred by air they should be transported in a pressurised aircraft (pressurised to sea level). According to Boyle's law, as altitude increases the gas within a closed system is subject to expansion, therefore pneumothorax enlargement can occur. For all forms of transport the patient should be accompanied by appropriate medical staff, experienced in needle thoracocentesis, in the event of tension pneumothorax development on route. Ideally the patient should have an aspiration catheter or ICC *in-situ*; however, this may not be possible due to limitations in local experience at the referring hospital.

Further management following admission

Removal of ICC

There is no evidence that clamping improves success rate or prevents recurrence[21]. A bubbling chest drain should never be clamped, as this may precipitate a tension pneumothorax. However, division of opinion exists anecdotally, and if the ICC is clamped for 4-6 hours prior to repeat CXR and possible removal, the child must remain on the ward throughout, with the nursing staff aware to unclamp should the child become symptomatic. The ICC should be removed using aseptic technique, and during full inspiration or if possible during a valsalva manoeuvre. If small bore ICC is used then a steristrip with tegaderm dressing is sufficient. A repeat CXR should be performed if symptoms recur following removal.

Indications for surgical referral

- Persisting air leak at 4 days
- 2nd ipsilateral pneumothorax
- 1st contralateral pneumothorax
- Bilateral pneumothoraces
- Patient intends to pursue a career with known risk factors (e.g. aviation, retrieval diver)
- Presence of apical bullae on CXR

Follow up

All patients should be discussed with the respiratory physician on call. Those patients who are managed conservatively will follow 'Discharge plan 1' pathway, all other patients will follow 'Discharge plan 2'.

Discharge Plan 1

- Discharge home with information card and analgesia
- Review by respiratory team via the Acute Review Clinic (ARC) within 1-2 days with a repeat CXR
- Telephone follow-up via the respiratory team in 4 weeks
- Review in respiratory clinic within 8 weeks with repeat CXR.

Discharge Plan 2

- Discharge home with information card and analgesia
- Telephone follow-up via the respiratory team in 4 weeks
- Review in respiratory clinic within 8 weeks with repeat CXR.

Advice prior to discharge from ED or the ward

- Smoking is related to risk of recurrence, with the lifetime risk of SP in smoking males ≤12% compared to 0.1% in non-smoking males[1], although less prominent in women. The majority of young adults, 80-86%, continue to smoke following SP[22]
- Please seek medical advice and/or return to emergency if patient develop clinical symptoms. Symptoms to look out for, namely chest pain, and acute shortness of breath.
- Not to fly until full re-expansion has occurred, with commercial airlines commonly stating 6 weeks. The main risk is related to the location of recurrence (on an aircraft) rather than the risk of recurrence itself.
- No scuba diving (unless bilateral pleurectomy)[23]

Episodes of Recurrence

- Patients who present with a 2nd episode of pneumothorax (based on radiological findings or suggested by clinical symptom history) require follow up in the respiratory outpatient clinic, and may warrant further investigation.
- Success of ICC decreases with subsequent episodes – 90% vs 52% vs 15% for initial, 1st recurrence and 2nd recurrence respectively. A CT scan should be performed after the 1st episode of ipsilateral recurrence to look for subpleural blebs. If subpleural blebs are present then the patient should be referred for a surgical consult.

Acknowledgements

The flowchart in this protocol has been revised based on recent publications, existing adult BTS and ACCP guidelines and thorough discussions across the Sydney Children's Hospital Network.

References

1. Bense L, Eklund G, Wiman LG. Smoking and the increased risk of contracting spontaneous pneumothorax. *Chest* 1987;92(6):1009-12.
2. Melton LJ, 3rd, Hepper NG, Offord KP. Incidence of spontaneous pneumothorax in Olmsted County, Minnesota: 1950 to 1974. *Am Rev Respir Dis* 1979;120(6):1379-82.
3. Robinson PD, Cooper P, Ranganathan SC. Evidence-based management of paediatric primary spontaneous pneumothorax. *Paediatric respiratory reviews* 2009;10(3):110-7; quiz 17.
4. Primrose WR. Spontaneous pneumothorax: a retrospective review of aetiology, pathogenesis and management. *Scott Med J* 1984;29(1):15-20.
5. Seremetis MG. The management of spontaneous pneumothorax. *Chest* 1970;57(1):65-8.
6. Bradley M, Williams C, Walshaw MJ. The value of routine expiratory chest films in the diagnosis of pneumothorax. *Arch Emerg Med* 1991;8(2):115-6.
7. Vail WJ, Alway AE, England NJ. Spontaneous pneumothorax. *Dis Chest* 1960;38:512-5.
8. Lippert HL, Lund O, Blegvad S, et al. Independent risk factors for cumulative recurrence rate after first spontaneous pneumothorax. *Eur Respir J* 1991;4(3):324-31.
9. Mitlehner W, Friedrich M, Dissmann W. Value of computer tomography in the detection of bullae and blebs in patients with primary spontaneous pneumothorax. *Respiration* 1992;59(4):221-7.
10. Sahn SA, Heffner JE. Spontaneous pneumothorax. *N Engl J Med* 2000;342(12):868-74.
11. Penketh AR, Knight RK, Hodson ME, et al. Management of pneumothorax in adults with cystic fibrosis. *Thorax* 1982;37(11):850-3.
12. Brown SGA, Ball EL, Perrin K, et al. Conservative versus Interventional Treatment for Spontaneous Pneumothorax. *N Engl J Med* 2020;382(5):405-15.
13. Robinson PD, Blackburn C, Babl FE, et al. Management of paediatric spontaneous pneumothorax: a multicentre retrospective case series. *Arch Dis Child* 2015;100(10):918-23.
14. Henry M, Arnold T, Harvey J. BTS guidelines for the management of spontaneous pneumothorax. *Thorax* 2003;58 Suppl 2:ii39-52.
15. Baumann MH, Strange C, Heffner JE, et al. Management of spontaneous pneumothorax: an American College of Chest Physicians Delphi consensus statement. *Chest* 2001;119(2):590-602.
16. Miscia ME, Lauriti G, Lisi G, et al. Management of Spontaneous Pneumothorax in Children: A Systematic Review and Meta-Analysis. *Eur J Pediatr Surg* 2020;30(1):2-12.
17. 17. Soccorso G, Anbarasan R, Singh M, et al. Management of large primary spontaneous pneumothorax in children: radiological guidance, surgical intervention and proposed guideline. *Pediatr Surg Int* 2015;31(12):1139-44.
18. MacDuff A, Arnold A, Harvey J, et al. Management of spontaneous pneumothorax: British Thoracic Society Pleural Disease Guideline 2010. *Thorax* 2010;65 Suppl 2:ii18-31.
19. Kaur S, Cortiella J, Vacanti CA. Diffusion of nitrous oxide into the pleural cavity. *Br J Anaesth* 2001;87(6):894-6.
20. Matsuura Y, Nomimura T, Murakami H, et al. Clinical analysis of reexpansion pulmonary edema. *Chest* 1991;100(6):1562-6.
21. Williams T. To clamp or not to clamp? *Nurs Times* 1992;88(18):33.
22. Smit HJ, Wienk MA, Schreurs AJ, et al. Do bullae indicate a predisposition to recurrent pneumothorax? *Br J Radiol* 2000;73(868):356-9.
23. British Thoracic Society Fitness to Dive Group SotBTSSoCC. British Thoracic Society guidelines on respiratory aspects of fitness for diving. *Thorax* 2003;58(1):3-13.

Procedures

1. Pneumothorax Aspiration

Equipment

- Sterile gloves and gown
- antiseptic solution (70% alcoholic chlorhexidine)
- sterile drapes
- oximeter to monitor saturations during insertion
- 1% lignocaine or equivalent
- 5 or 10mL syringe with 25G and 21G needles for administration to superficial and deeper layers respectively (longer needles may be required for more obese patients)
- scalpel for incision
- 9G Cook aspiration catheter or 18G intravenous (IV) cannula
- 3 way connector (with outlets in "off" position)
- set this up prior to starting so that this can be quickly attached to the aspiration catheter or IV cannula when inserted, and also check that adaptors are correct for connection to the aspiration catheter used.

Procedure

1. Check patient details
2. Explain procedure to the patient/parent
3. Obtain patient/parent consent. (**Note:** If procedure is deemed life saving then consent is not required)
4. Confirm side and positioning of pneumothorax by clinical signs and CXR
5. Mark position for aspiration catheter insertion on patient (ensure this is done in the position that the drain is being inserted to avoid movement of landmarks)
   - **Axillary approach**
     - **i.** 4th or 5th intercostal space in midaxillary or anterior axillary line in the region bounded by the:
       1. lateral border of pectoralis major
       2. anterior border of latissimus dorsi
       3. a line superior to the horizontal level of the nipple (in obese patients or pubertal females the rib spaces should be counted as the nipple line is unreliable)
       4. the apex in the axilla
     - **ii.** recline patient at 30 degrees, with arm raised and behind head to expose axilla or alternatively sit patient upright leaning over an adjacent table on a pillow.

- **Anterior approach** (should only be considered for apical collections not accessible using axillary approach)
    1. 2nd intercostal space mid clavicular line
    2. patient reclining at 30 degrees on bed

6. Administer appropriate pre-medication
7. Monitor respiratory rate, heart rate and oxygen saturations throughout insertion
8. Infiltrate skin and deeper tissues including parietal pleura with local anaesthetic and wait for onset of action
9. Insert the aspiration catheter, using the seldinger technique, or IV cannula, above the upper edge of the rib (to avoid the neurovascular bundle which runs underneath the rib) and angle towards the apex of the lung. Aspirate as move through tissue layers.
10. Aspirate air using 3 way valve and 50mL syringe until no further air can be removed. Document cumulative total air aspirated (mL).
11. If using IV cannula then remove following aspiration.
12. If using Aspiration catheter, occlude and adequately secure until repeat CXR reviewed.
13. Obtain CXR to assess success of procedure

2. Chest drain insertion

Equipment required

- Sterile gloves and gown
- antiseptic solution (70% alcoholic chlorhexidine)
- sterile drapes
- oximeter to monitor saturations during insertion
- 1% lignocaine or equivalent
- 5 or 10mL syringe with 25G and 21G needles for administration to superficial and deeper layers respectively (longer needles may be required for more obese patients)
- scalpel for incision
- appropriately sized Pigtail Intercostal Chest Catheter (ICC)
- underwater seal system
    - sterile tubing, adaptors, underwater seal drainage system primed according to manufacturers instructions, 500mL bottle normal saline, adhesive strapping
    - set this up prior to starting so that this can be quickly attached to the chest drain when inserted, and also check that adaptors are correct for connection to the chest drain used
- tube clamps
- securing equipment for drain

- non-absorbable suture material, straight forceps, scissors if stitching
- commercially available tube tether or adhesive strapping

Procedure

1. Check patient details
2. Explain procedure to the patient/parent
3. Obtain patient/parent consent (**Note:** If procedure is deemed life saving then consent is not required)
4. Confirm side and positioning of pneumothorax by clinical signs and CXR
5. Mark position for ICC insertion on patient (ensure this is done in the position that the drain is being inserted to avoid movement of landmarks)
   - **Axillary approach**
     - **i.** 4th or 5th intercostal space in midaxillary or anterior axillary line in the region bounded by the
       1. lateral border of pectoralis major
       2. anterior border of latissimus dorsi
       3. a line superior to the horizontal level of the nipple (in obese patients or pubertal females the rib spaces should be counted as the nipple line is unreliable)
       4. the apex in the axilla
     - **ii.** recline patient at 30 degrees, with arm raised and behind head to expose axilla or alternatively sit patient upright leaning over an adjacent table on a pillow
   - **Anterior approach** (should only be considered for apical collections not accessible using axillary approach)
     - **i.** 2nd intercostal space mid clavicular line
     - **ii.** patient reclining at 30 degrees on bed
6. Administer appropriate pre-medication
7. Monitor respiratory rate, heart rate and oxygen saturations throughout insertion
8. Infiltrate skin and deeper tissues including parietal pleura with local anaesthetic and wait for onset of action
9. Make a small incision in the skin to aid insertion of the ICC (diameter of incision should be guided by the diameter of the ICC).
10. Insert the ICC, using the seldinger technique, above the upper edge of the rib (to avoid the neurovascular bundle which runs underneath the rib) and angle towards the apex of the lung. Aspirate as move through tissue layers.
11. Clamp the ICC following insertion to facilitate controlled evacuation of air
12. Connect to underwater seal system apparatus

13. Secure chest drain using stitches or commercial tethering system
14. Obtain CXR to assess the position of the ICC tip

Potential Complications of ICC insertion include

- Pain (ensure adequate pain control to facilitate full expansion of lung with breathing)
- Pleural infection (monitor temperature 4hrly and inspect insertion site each nursing shift)
- Incorrect placement (assessment of position with imaging)
- Haemorrhage (for medical review if blood drains into catheter)
- Hypotension (monitor blood pressure (BP) 4hrly along with heart rate (HR))
- Pulmonary oedema following lung re-expansion (rare – re-image if concerns)

3. Needle Thoracocentesis

Equipment

- 18G intravenous cannula
- 10mL or 20mL syringe
- alcohol swab
- tape

Procedure

1. Identify the second intercostal space in the midclavicular line on the side of the pneumothorax (the opposite side to the direction of tracheal deviation).
2. Swab the chest wall with surgical prep or an alcohol swab.
3. Attach the syringe to the cannula.
4. Insert the cannula into the chest wall, just above the rib below, aspirating all the time.
5. If air is aspirated remove the needle, leaving the plastic cannula in place.
6. Tape the cannula in place and proceed to chest drain insertion as soon as possible.

Paediatric Spontaneous Pneumothorax – Factsheet

What is a pneumothorax?

The area between your lung and chest wall is called the pleural space. A pneumothorax occurs when there is an air leak which causes air to become trapped in the pleural space. This pocket of air can apply pressure on the lungs causing part or all of it to collapse.

What causes a pneumothorax?

Primary spontaneous pneumothorax

- These often occur suddenly with no clear cause in an otherwise healthy child
- It is most commonly seen in tall, thin boys
- Sometimes these cases may be caused by an underlying area of weakness in the lung such as a bleb or cyst

Secondary spontaneous pneumothorax

- This air leak occurs due to weakness in the lungs secondary to an existing lung condition
- Some examples include; asthma, cystic fibrosis, and Marfan's Syndrome

Trauma

- Air leaks can also occur due to direct injury or impact to the lung
- Some examples include car crash, direct chest injuries, broken ribs

What are the signs and symptoms of a pneumothorax?

Symptoms can vary however they commonly include:

- Sudden, sharp, stabbing chest pain worse on breathing
- Feeling short of breath
- Cough
- Fast shallow breathing
- Racing heart beat

How is it diagnosed?

A chest x-ray is a quick and easy and is often all that is needed to make the diagnosis.

Your doctor may refer you further tests and repeat x-rays depending on the situation.

How is it treated?

Treatment will depend on several factors:

- The cause or type of the pneumothorax
- The severity of symptoms
- Signs of an expanding air leak

Most case only require conservative treatment.

Conservative treatment

Often these episodes will heal on its own with treatment of symptoms without invasive treatment or a stay in hospital if. Pain relief medication and oxygen may help relief symptoms.

Surgical Intervention treatment

The collection of air may be removed using a chest drain or needle. A chest drain is a plastic tube that is inserted through the chest wall into the pleural space. This drain is left in place allowing the trapped air to drain out but not re-enter, therefore allowing the lung to re-inflate.

Can it happen again?

Most children do well after treatment however there is a chance your child may have another episode. If another pneumothorax happens on the same side, your child may need to be referred to the surgeons for further tests and operation.

There are certain activities that may increase the risk of recurrence including: smoking, scuba diving, air travel and strenuous physical activities for 6 weeks or medical clearance.

What to do?

Your doctor will arrange follow-up for you with the Respiratory team at The Children's Hospital at Westmead with a repeat chest x-ray upon discharge.

Please seek immediate medical advice and/or return to emergency if your child develops the following symptoms:

- Worsening chest pain
- Difficulty breathing or shortness of breath
- Bluish tinge around their mouth
- Faint
- Fast heart beat

Remember

- Smoking is related to risk of recurrence
- Please seek medical advice and/or return to emergency if your child develops the following symptoms:
  - Worsening chest pain
  - Difficulty breathing or shortness of breath.
- **No flying** for **at least 6 weeks** or until cleared by your doctor, due to the risk of lung collapse.
- **No scuba diving** for **at least 6 weeks**, unless cleared by your doctor
- **No strenuous physical activity** or contact sports for **at least 6 weeks** or clear by your doctor